ISSN 2395-1621

Detection Of Brain Metastases In Magnetic Resonance Imaging

#1Snehal. Sachin Pattewar, #2Yogita Vitthal. Sarade, #3Priyanka Vasudeo. Shinde, #4Dr.P.S.Arora

1snehalpattewar11.sp@gmail.com

#12345DEPARTMENT OF ELECTRONICS & TELECOMMUNICATION

JSPM's IMPERIAL COLLEGE OF ENGINEERING & RESEARCH
WAGHOLI, PUNE- 412207.

ABSTRACT

Early detection of brain metastases increases survival in patients with cancer, since image-guided radiosurgery is the most widely used treatment. As support for the qualitative diagnosis made by radiologists, Computer Assisted Diagnosis provides a quantitative and reproducible analysis. This article reviews the methods for an automatic detection of brain metastases in contrast-enhanced T1-weighted magnetic resonance imaging. Model-based methods detect metastases due to their high degree of similarity with models representing their morphology, mainly templates. On the other hand, methods based on brain symmetry and intensity search intensity differences between both brain hemispheres with respect to the symmetry axis. Model-based methods are more commonly used because they allow the detection of metastases of a wider range of measures.

ARTICLE INFO

Article History

Received: 1st June 2017

Received in revised form :

1st June 2017

Accepted: 4th June 2017

Published online :

4th June 2017

I. INTRODUCTION

Early detection of brain metastases increases survival in patients with cancer, since image-guided radiosurgery is the most widely used treatment. As support for the qualitative diagnosis made by radiologists, Computer Assisted Diagnosis provides a quantitative and reproducible analysis. This article reviews the methods for an automatic detection of brain metastases in contrast-enhanced T1-weighted magnetic resonance imaging. Model-based methods detect metastases due to their high degree of similarity with models representing their morphology, mainly templates. On the other hand, methods based on brain symmetry and intensity search intensity differences between both brain hemispheres with respect to the symmetry axis. Model-based methods are more commonly used because they allow the detection of metastases of a wider range of measures.

II. LITERATURE SURVEY

2.1 The Paper Entitled "Application of fuzzy system in segmentation of MRI brain tumor"

By:M. Hanmandlu, D. Vineel and G. Singh, IICAI-07, pp. 344-358, 2008.

Proposed: Tumor volume is an important diagnostic indicator in treatment planning of brain tumors. The measurement of brain tumor volume could assist tumor staging for effective treatment surgical planning. Imaging plays a central role in the diagnosis and treatment planning of the brain tumor. In this study a semi – automated system for brain tumor volume measurements is developed based on MR imaging. This method is applied to 8 tumor containing MRI slices from 2 brain tumor patients' data sets and satisfactory segmentation results are achieved. We demonstrate a stable, 3D level-set evolution framework applied to automatic segmentation of brain tumors in MRI, using a probability map of tumor versus background to guide the snake propagation. But the semiautomated method generates results that have higher level of agreement with the manual raters. Preliminary comparisons demonstrate that the semi -automatic segmentation comes close to the manual expert segmentation. Further work is in progress to investigate the sensitivity towards initialization and parametersettings on a larger set of tumor datasets.

2.2 The Paper Entitled "Quick Detection of Brain Tumors and Edemas: A Bounding Box Method Using Symmetry"

By:M. E. Brummer, R. M. Mersereau, R. L. Eisner, R. J. Lewine, IEEE Trans. Medical Imaging, vol. 12, no. 2, pp. 153 – 166, 1993

Proposed: FBB is a novel fast segmentation technique that uses symmetry to enclose an anomaly (typically, tumors or edema) by a bounding box within an axial brain MR image. This approach avoids the challenge of dealing with the variation of intensities among different MR image slices. Moreover, FBB does not need image registration. We have illustrated that some standard segmentation algorithms (such as active contour without edges or normalized graph cut) can delineate exact tumor boundary or edema if these algorithms are applied only within the bounding box. This region based approximate segmentation technique can explore new opportunities of effective MR database indexing system. The resulting method is very fast, robust and reliable for indexing tumor or edema images for both archival and retrieval purposes and it can use as a vehicle for further clinical investigations.

2.3 The Paper Entitled "3D brain tumor segmentation in MRI using fuzzy classification, symmetry analysis and spatially constrained deformable models"

By:A.W. Toga, P.M. Thompson, M.S. Mega, K.L. Narr, R.E. Blanton, 204 (4) (2001) 267–282.

Proposed: We have developed a hybrid segmentation method that uses both region and boundary information of the image to segment the tumor. We compared a fuzzy classification method and a symmetry analysis method to detect the tumors and we have used a deformable model constrained by spatial relations for segmentation refinement. This work shows that the symmetry plane is a useful feature for tumor detection. In comparison with other methods, our approach has some advantages such as automation (in the symmetry analysis method, a reduced interaction is required to select the appropriate peaks in the difference histogram), and more generality with respect to the wide range of tumors.

l Salmero ´n-Sa ´nchezc and David Moratala aCentre for Biomaterials and Tissue Engineering, Universitat Polite `cnica de Vale `ncia, Valencia, Spain; bDepartment of Radiology, Fundacio ´n InstitutoValenciano de Oncologı ´a, Valencia, Spain; cDivision of Biomedical Engineering, School of Engineering, University of Glasgow, Glasgow, UK.

Proposed: Anisotropy is one of the most meaningful determinants of biomechanical behaviour. This study employs micro-computed tomography (mCT) and image techniques for analysing the anisotropy of regenerative medicine polymer scaffolds. For this purpose, three three-dimensional anisotropy evaluation image methods were used: ellipsoid of inertia (EI), mean intercept length (MIL) and tensor scale (t-scale). These were applied to three patterns (a sphere, a cube and a right prism) and to two polymer scaffold topologies (cylindrical orthogonal pore mesh and spherical pores). For the patterns, the three methods provided good results. Regarding the scaffolds, EI mistook both topologies (0.0158, [20.5683; 0.6001]; mean difference and 95% confidence interval).

2.4 The Paper Entitled " A Review of Image Segmentation Methods On Brain MRI For Detection Of Tumor And Related Abnormalities"

By:M. Sonka, K. Imrie and Y. Xie, , Proceedings of the IEEE transaction on Medical Images, Iowa City, IA, December 1996

Proposed: Image segmentation is widely used in biomedical image analysis and is crucial for study of anatomical structure, tissue volumes computation, diagnosis of abnormalities, pathology, treatment planning and computer-aided surgery. In this survey paper various automatic and semi-automatic segmentation and tissue classification methods for brain using MRI has been studied. The ultimate objective is to device new techniques of image analysis and focus on the future advancement of medical image processing in medicine and healthcare. This paper has studied examples of the most popular methods of segmentation rather than surveying over all the different techniques available. The key idea is to identify the most viable methods for future development of better and effective segmentation techniques that will assist radiologist in accomplishing an in-depth investigation of the brain at a significantly reduced time. The observation from the studies suggested that any future method may be hybrid of a combination of the methods discussed

2.5 The Paper Entitled"A SURVEY ON SEGMENTATION TECHNIQUES"

By: JishaKrishnan Dept. of ComputerScience And Engineering SCT College of Engineering Trivandrum,India jishkrish@gmail.com RejimolRobinsonDept of ComputerScience And Engineering SCT College of Engineering Trivandrum,India

Proposed: Interstitial lung disease is one of the main treat to the health .Computer Tomography is used for assessment of interstitial lung disease .But sometimes it is difficult to visually interpret because of the crossing and overlapping of the vessels in the CT. There a vessel segmentation techniques is used for detecting lung disease Different techniques is available for lung segmentation for diagnosing lung disease. Vessel tree extraction is one of the challenging technique for several years and it is under open research. Automatic segmentation of vessel tree is one of the most important requirement for Computer Aided Diagnosis(CAD).In this paper we investigate lung vessel extraction and enhancement technique and present the capabilities of most important algorithms concerning lung vessel segmentation.

2.6 The Paper Entitled"A Review on the Analysis Techniques"

By:H. Mahersia1, M. Zaroug1 1Department of Computer Science, College of science and arts of Baljurashi, Albaha University, Albaha, Kingdom of Saudi Arabia L. Gabralla2 2Faculty of Computer Science & Information Technology University of Science &Technology, Khartoum, Sudan

Proposed: Lung nodules are potential manifestations of lung cancer, and their early detection facilitates early treatment and improves patient's chances for survival. For this reason, CAD systems for lung cancer have been proposed in several studies. All these works involved mainly three steps to detect the pulmonary nodule: preprocessing, segmentation of the lung and classification of the nodule candidates. This paper overviews the current state-of-the-art regarding all the approaches and techniques that have been investigated in the literature. It also provides a comparison of the performance of the existing approaches.

III.BLOCK DIAGRAM

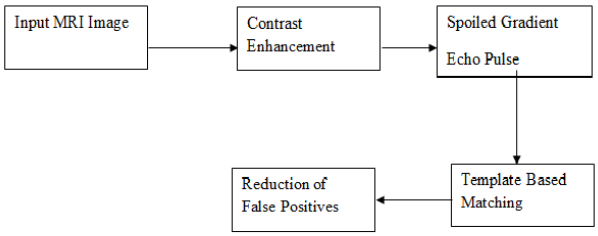

Fig 4.1 Block diagram of the system

4.1 Input MRI Image:

Magnetic resonance imaging (MRI) is a medical imaging technique used in radiology to image the anatomy and the physiological processes of the body in both health and disease. MRI scanners use strong magnetic fields, radio waves, and field gradients to form images of the body.

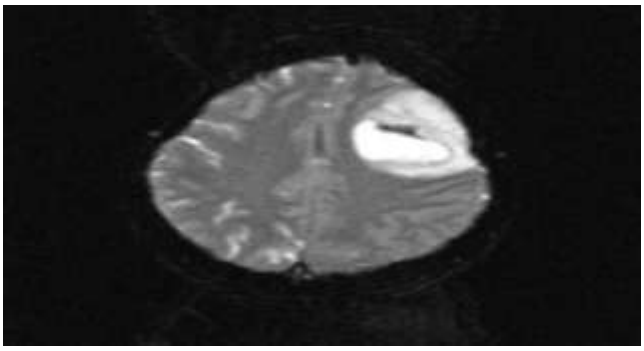

Fig .2 : Input MRI Image

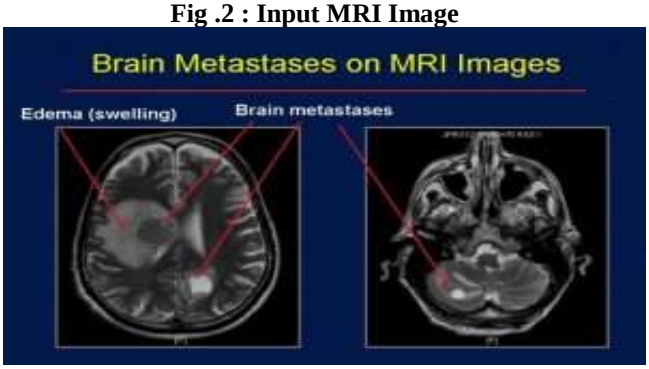

Fig .3 :Brain Metastases on MRI Image

4.2 Contrast enhancement:

Image enhancement techniques have been widely used in many applications of image processing where the subjective quality of images is important for human interpretation. Contrast is an important factor in any subjective evaluation of image quality. Contrast is created by the difference in luminance reflected from two adjacent surfaces. In other words, contrast is the difference in visual properties that makes an object distinguishable from other objects and the background. In visual perception, contrast is determined by the difference in the colour and brightness of the object with other objects.

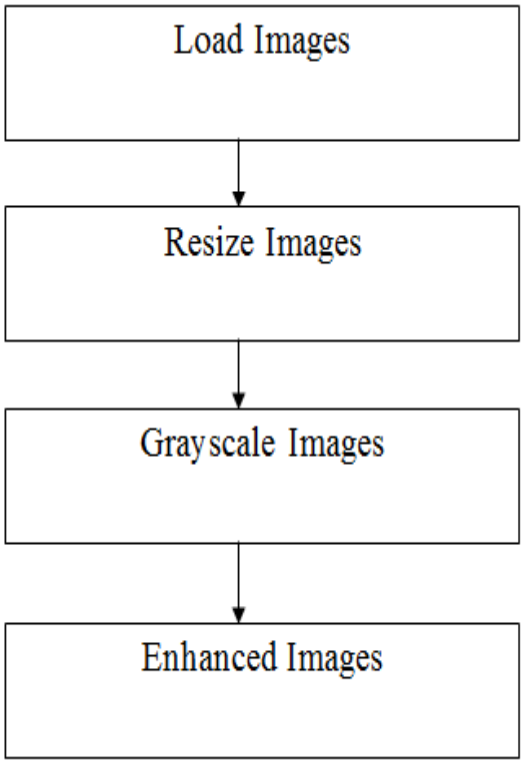

Fig .4 :Flow Diagram of Contrast Enhancement:

4.2.1 Load Images:

Read the grayscale images: Also read in an indexed image:

4.2.2 Resize Images:

To make the image comparison easier, resize the images to have the same width. Preserve their aspect ratios by scaling their heights

1) 4.2.3: Enhance Grayscale Images:

Using the default settings, compare the effectiveness of the following three techniques:

- Imadjust increases the contrast of the image by mapping the values of the input intensity image to new values such that, by default, 1% of the data is saturated at low and high intensities of the input data.

- Histeq performs histogram equalization. It enhances the contrast of images by transforming the values in an intensity image so that the histogram of the output image approximately matches a specified histogram (uniform distribution by default).
- Adapthisteq performs contrast-limited adaptive histogram equalization. Unlike histeq, it operates on small data regions (tiles) rather than the entire image. Each tile's contrast is enhanced so that the histogram of each output region approximately matches the specified histogram (uniform distribution by default). The contrast enhancement can be limited in order to avoid amplifying the noise which might be present in the image.

4.3 Spoiled gradient echo pulse sequence (SPGR):

In magnetic resonance imaging, the enhancement of SPGR images was less than that of the SE(spin echo) images under the same conditions, but not to a fatal degree, and thin slice SPGR imaging is therefore considered to be useful for detecting small lesions, when given a high dose of contrast agent and a suitable scanning delay time.

Rapid imaging sequences are characterized by a fast train of excitation and gradient pulses. Between excitation pulses or within TR, the magnetization is not able to return to its thermal equilibrium. As a consequence, excitation pulses will influence both the remaining transversal and the remaining longitudinal magnetization. The steady-state magnetization of a multi pulse experiment is thus a mixture or superposition of different transversal and longitudinal states, and the acquired image amplitude becomes a complex function of the investigated tissue's relaxation properties.

IV. RESULT

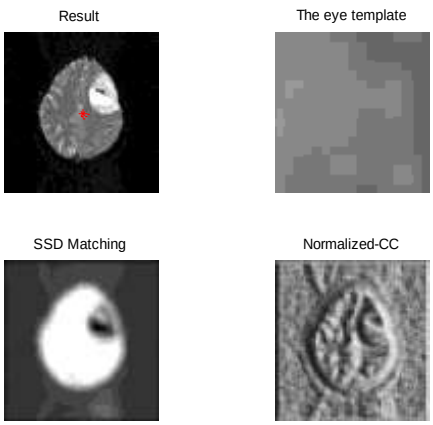

Fig .5 Final outcome

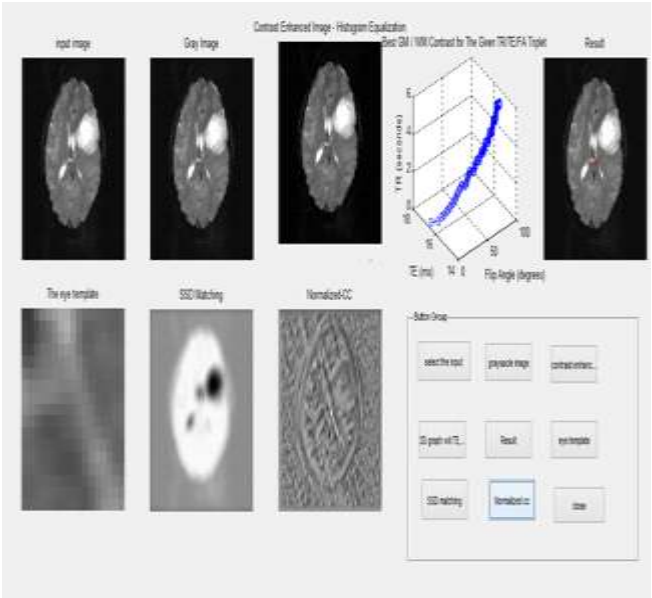

Fig 6 Final display after performing GUI.

V. CONCLUSION

The result demonstrate the automated detection method for metastatic brain tumours using CAD with 3D template matching method.The results of our study demonstrate that accurate automated detection of metastatic brain tumours.Such detection method can possibly assist radiologists during the interpretation and detection of MR images of metastatic brain tumours.

Segmentation technique that uses symmetry to enclose an anomaly (typically,tumors or edema) by a bounding box within an axial brain MR image. We utilize a novel region based score function, which uses Bhattacharya coefficient to compute local histogram similarity between test and reference (sub) images. We have analytically explained the behavior of the score function that effectively locates the brain tumors or edema quickly, showing how it exploits the symmetry of the axial brain MR image slices along the medial axis.

Advanced template matching algorithms allow to find occurrences of the template regardless of their orientation and local brightness.Template Matching techniques are flexible and relatively straightforward to use, which makes them one of the most popular methods of object localization.

REFERENCES

1. M. Hanmandlu, D. Vineel and G. Singh, “Application offuzzy system in segmentation of MRI brain tumor”IICAI-07, pp. 344-358, 2008.
2. M. E. Brummer, R. M. Mersereau, R. L. Eisner, R. J. Lewine, “The Paper Entitled "Quick Detection of Brain Tumors and Edemas: A Bounding Box Method Using Symmetry"IEEE Trans. Medical Imaging, vol. 12, no. 2, pp. 153 – 166, 1993
3. A.W. Toga, P.M. Thompson, M.S. Mega, K.L. Narr, R.E. Blanton, "3D brain tumor segmentation in MRI

using fuzzy classification, symmetry analysis and spatially constrained deformable models " 204 (4) (2001) 267–282.

4. M. Sonka, K. Imrie and Y. Xie, ― " A Review of Image Segmentation Methods On Brain MRI For Detection Of Tumor And Related Abnormalities ", ‖ Proceedings of the IEEE transaction on Medical Images, Iowa City, IA, December 1996

5. R. Ambrosini, and P. Wang, ”Computer-aided detection of metastatic brain tumors using automated three-dimensional template matching.” Journal of Magnetic Resonance Imaging, Vol. 31(1), pp. 85-93, 2010.

6. D. Cobzas, N. Birkbeck, M. Schmidt, M. Jagersand, and A. Murtha, “3D Variational Brain Tumor Segmentation using a High Dimensional Feature Set” International Conference on Computer Vision, 2007.

7. Shanthi K. J , M. Sasi Kumar , C. Keshavdas, Comparison of Two Methods for Automatic Segmentation of Brain MRI based on 2D Seed Growth and Two Stage FCM Algorithm, IEEE, DOI 10.1109/CIMCA.2008.171, CIMCA 2008.

8. K.Selvanayaki, Dr. M. Karnan, CAD System for Automatic Detection of Brain Tumor through Magnetic Resonance Image-A Review, International Journal of Engineering Science and Technology, ISSN: 0975-5462, Vol. 2(10), 2010, pp 5890-5901

9. Neeraj Sharma, Lalit M Aggarwal, Automated medical image segmentation techniques, Journal of Medical Physics, Volume 35 Issue 1 pp 3-14, 2010.

10. R. B. Dubey, M. Hanmandlu, ShantaramVasikarla, Evaluation of Three Methods for MRI Brain Tumor Segmentation, Eighth International Conference on Information Technology: New Generation IEEE, pp 494-499, 2011.

11. Prof. Samir Kumar Bandyopadhyay, A Survey on Brain Image Segmentation Methods, Journal of Global Research in Computer Science, Volume 2, No. 2, pp 4-7, February 2011.

